Memorial Sloan Kettering Cancer Center

Overview of Early Stage Endometrial Cancer

Stephanie Alvarado, PA-C

Farrell Dearie, PA-C

December 9, 2022

Uterine Cancer

Types

1) **Endometrial cancer (>90% of uterine cancers, most common Gyn cancer)**
   -cancer arising in the inner lining (endometrium)
   -more favorable prognosis
2) **Uterine sarcoma (<10% of uterine cancers)**
   -cancer arising in the middle layer (myometrium) or connective tissue part of the endometrium
   -poorer prognosis

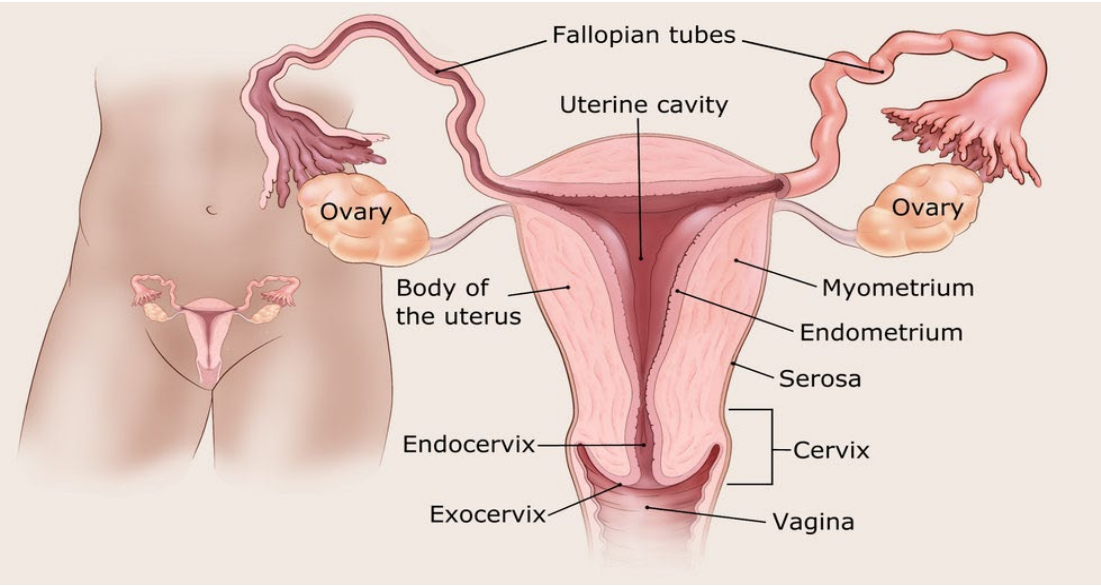

UpToDate – Endometrial carcinoma: Clinical features, diagnosis, prognosis, and screening, 2022
UpToDate – Endometrial carcinoma: Epidemiology, risk factors, and prevention
UpToDate – Overview of endometrial carcinoma, 2022
UpToDate – Endometrial carcinoma: Epidemiology, risk factors, and prevention, 2022
https://www.mayoclinic.org/diseases-conditions/endometrial-cancer/symptoms-causes/syc-20352461
UpToDate – Surgical female pelvic anatomy: Uterus and related structures, 2022
https://www.cancer.org/cancer/endometrial-cancer/about/what-is-endometrial-cancer.html

Endometrial Cancer

Epidemiology

- Identified in ~3% of women in the US
- **4th most common cancer in females in the US**
- Incidence highest between age 60 and 70
  - 2-5% diagnoses occur prior to age 40
- In US SEER data (2015-2019), Black women had the highest age-adjusted incidence of endometrial cancer, compared with White, Hispanic, and Asian American women
  - Incidence of endometrial cancer in females with uterus in situ likely underestimated as data were not adjusted for prevalence of hysterectomy

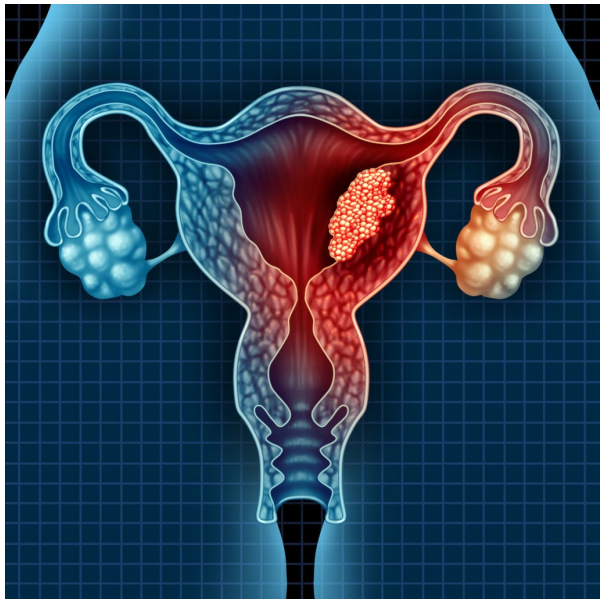

UpToDate – Overview of endometrial carcinoma, 2022
UpToDate – Endometrial carcinoma: Epidemiology, risk factors, and prevention, 2022
https://www.saintjohnscancer.org/gynecology/conditions-we-treat/uterine-cancer/

Endometrial Cancer

Histology

Endometrial Cancer Histological Sub-types:

- **Endometrioid (most common)**
  - -FIGO classification system
    - Low [**-Grade 1 (favorable prognosis)**
      -Grade 2 (favorable prognosis)
    - High [-Grade 3 (poorer outcomes)
- Serous, clear cell, mixed carcinoma, undifferentiated/dedifferentiated carcinoma, carcinosarcoma, other (rare)

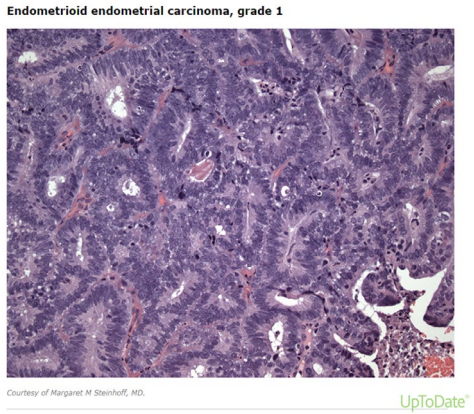

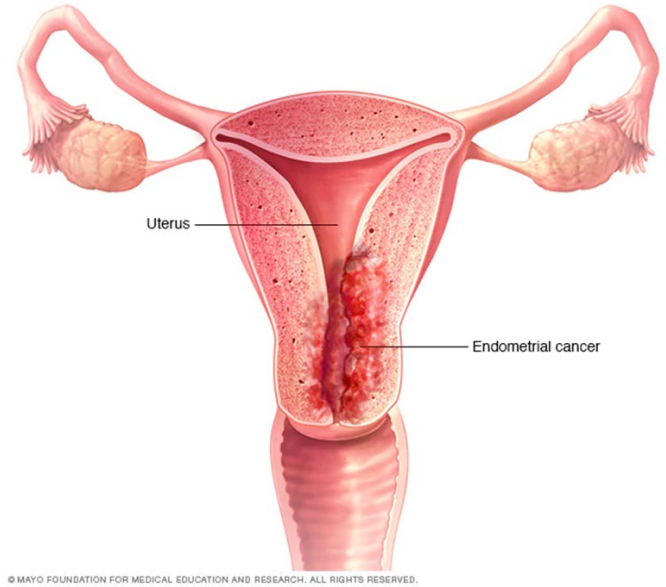

UpToDate – Endometrial carcinoma: Pathology and classification, 2022
https://www.mayoclinic.org/diseases-conditions/endometrial-cancer/symptoms-causes/syc-20352461
https://www.cancer.org/cancer/endometrial-cancer/about/what-is-endometrial-cancer.html

Low Grade Endometrioid Endometrial Cancer

Risk Factors

Increased Estrogen Levels (chronically)

Exogenous Sources
- Unopposed estrogen therapy
- Tamoxifen use

Endogenous Sources
- Chronic anovulation
- Obesity
- Estrogen-secreting tumors
- Early menarche/late menopause

Inherited Factors

Hereditary Factors
- Lynch Syndrome

Other Possible Inherited Factors
- Cowden Syndrome
- First degree relative with EC
- BRCA mutation carriers

Other Potential Factors

- Phytoestrogens
- History of breast cancer/pelvic RT
- DM/HTN
- Cyclic combined HRT (equine estrogen 0.625mg daily + medroxyprogesterone acetate 10mg x 12 days/month)

UpToDate – Overview of endometrial carcinoma, 2022
UpToDate – Endometrial carcinoma: Epidemiology, risk factors, and prevention, 2022

Low Grade Endometrioid Endometrial Cancer

Clinical Presentation

- **Abnormal uterine bleeding (~75-90% of patients)**
- Abnormal pap smear
  - Endometrial cells present, AGC, or adenocarcinoma
- Incidental finding
  - Imaging
    - Thickened endometrium on US, CT, or MRI
  - Surgery
    - After hysterectomy or intraoperatively

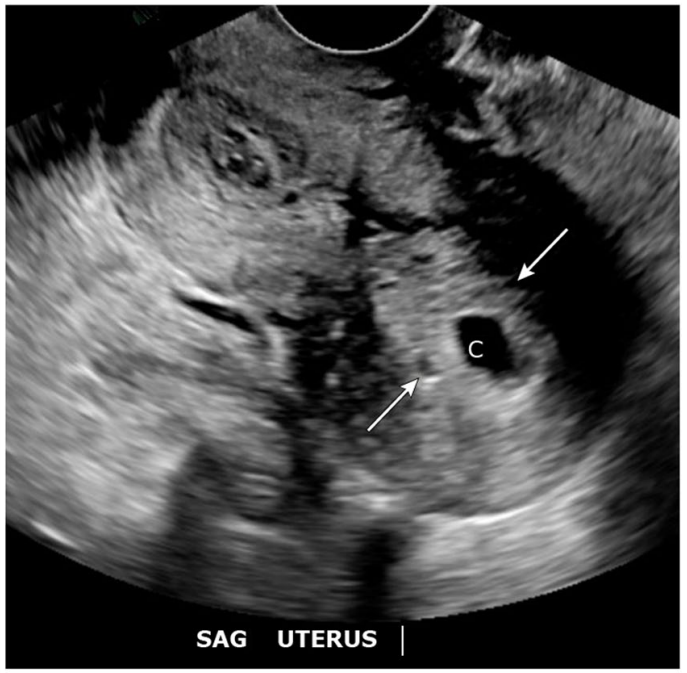

UpToDate – Endometrial carcinoma: Clinical features, diagnosis, prognosis, and screening, 2022
UpToDate - Overview of the evaluation of the endometrium for malignant or premalignant disease, 2022

Low Grade Endometrioid Endometrial Cancer

Clinical Findings

- **Physical exam**
  - Typically normal in early stage
- **Labs**
  - Typically normal
  - Possible anemia (significant AUB)
- **Pelvic Ultrasound**
  - **Post-menopausal:** thickened endometrium (>4mm)
  - **Pre-menopausal:** cancer risk not correlated with endometrial thickness

Diagnosis

- **Endometrial sampling for pathology**
  - Endometrial biopsy
  - Endometrial curettage (D&C)
  - Hysterectomy

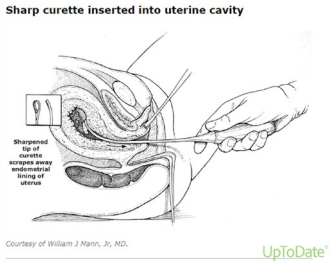

UpToDate – Endometrial carcinoma: Clinical features, diagnosis, prognosis, and screening, 2022
UpToDate – Dilation and Curettage, 2022
UpToDate – Overview of the evaluation of the endometrium for malignant or premalignant disease, 2022

Low Grade Endometrioid Endometrial Cancer

Role of surgery

- All women with resectable endometrial carcinoma should undergo surgery
  - remove cancer and determine need for adjuvant therapy
- **Surgery curative in low grade (grade 1-2) early stage endometrioid endometrial cancer**
  - Intermediate to high-risk of recurrence-->adjuvant chemo +/- RT
- Treatment after surgery decided by risk of recurrence, based on: stage, histology, grade, tumor size, patient age, and other factors

Schematic diagram illustrating endometrial cancer staging

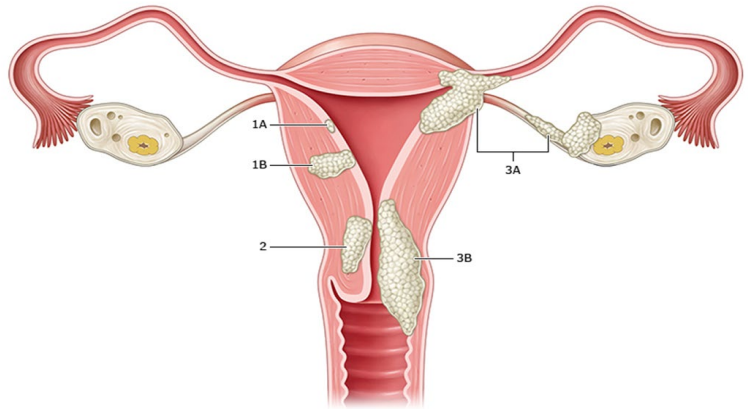

- Stage 1A tumor limited to the endometrium or invading less than half the myometrium.
- Stage 1B tumor invading one half or more of the myometrium.
- Stage 2 tumor invading the stromal connective tissue of the cervix but not extending beyond the uterus. Does NOT include endocervical glandular involvement.
- Stage 3A tumor involving the serosa and/or adnexa (direct extension or metastasis).
- Stage 3B vaginal involvement (direct extension or metastasis) or parametrial involvement.

From: Uterus and Cervix. In: Genitourinary Radiology, 6th ed, Dunnick NR, Newhouse JH, Cohan RH, Maturen KE (Eds), Wolters Kluwer, Philadelphia 2018. Copyright © 2018. Reproduced with permission from Wolters Kluwer Health. Unauthorized reproduction of this material is prohibited.

UpToDate®

UpToDate – Endometrial carcinoma: Staging and surgical treatment, 2022
UpToDate – Overview of endometrial cancer, 2022

Low Grade Endometrioid Endometrial Cancer

Surgical treatment

- **Total hysterectomy, bilateral salpingo-oophorectomy & lymphadenectomy**
  - ***Disease confined to the uterus (early stage) → MIS (Robotic) approach***
  - *Extra-uterine disease → laparotomy with possible cytoreductive surgery*

UpToDate – Endometrial carcinoma: Staging and surgical treatment, 2022
UpToDate – Overview of endometrial cancer, 2022
https://spectrum.ieee.org/new-da-vinci-xi-surgical-robot

Positioning and draping of the Robotic surgery Patient

- Patient is positioned in supine and lithotomy (on back & legs in stirrups) on anti-slip device
- arms tucked at the sides/Velcro strap across chest
- Patient placed in 28 degrees of Trendelenburg (allows abdominal contents to move out of the pelvis)
- Table positioning is tested prior to sterile draping to ensure patient safety

https://static.wixstatic.com/media/8bd03c_bc25a6fd1fc24b809d3d8f4c7c27a06d~mv2.jpg/v1/fill/w_352,h_344,al_c,q_80,usm_0.66_1.00_0.01,enc_auto/Image-empty-state.jpg

How we enter the abdomen wall

Blind entry with Veress needle

- Blind entry
- Most common point of entry is the LUQ **(Palmers Point)**

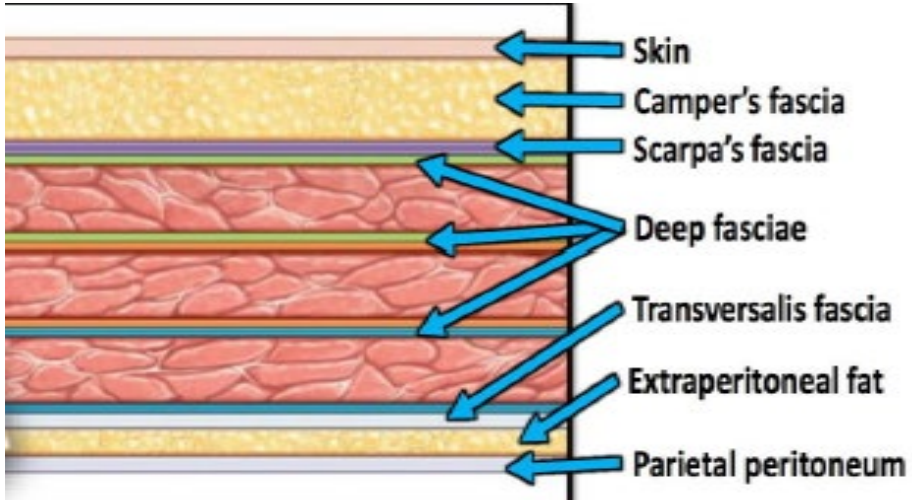

Visual entry/Optiview/Visiport or Direct optical trocar

- A reasonable and safe approach for the obese patient
- Allows you to see all the layers of the abdomen when entering

Hassan technique (open technique/cutdown)

- Has it limits due to thick abdominal wall
- Ideal for the patient with adhesions from previous surgery

https://d1yboe6750e2cu.cloudfront.net/i/e949733c81e2d7c4a963bb61a62686e9719cba5a

How we insufflate the abdomen

- Utilization of CO_2 gas to distend the abdominal cavity during Robotic surgery
- Closed loop system that prevents loss of pneumoperitoneum during the procedure
- Constant inflow of gas/smoke evacuation & a calibration system that ensures that we never over pressurize the abdominal cavity

Uterine manipulation/ ICG

Uterine Manipulator

Uterine manipulation Steps:

- Sound uterus
- Dilate cervix
- Insert manipulator and inflate balloon
- Movements are smooth small wristed motions

Sentinel Node Mapping with ICG (Indocyanine green)

- Used to identify the node where cancer has most likely spread first (sentinel node). In these cases, **ICG dye** is injected directly into the cervix at 3 and 9 o'clock and can result in mapping 10-20 minutes later. The ***firefly*** system identifies the ICG. (near-infrared imaging)

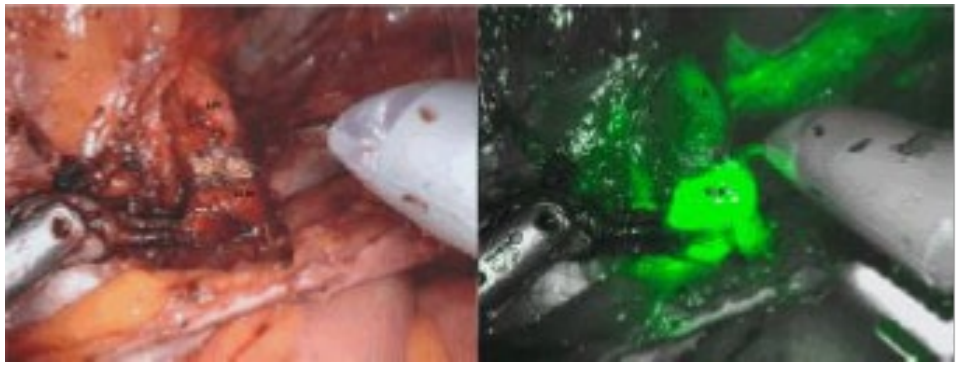

http://www.conmed.com/endosurgery_vcare.php
https://www.oatext.com/img/SRJ-2-151-g003.gif
https://gpm.amegroups.com/article/view/6065/html

Robotic Port Placement for GYN

- **A**-Camera
- **B/C/D**-8mm robotic trocars
- **E**-12 mm assist port
- Ports are place 8-10mm apart with 2-3 finger breadths from the ASIS on the most lateral ports and the LUQ port placed 2-3 finger breadths from the rib line

https://www.dreamstime.com/photos-images/female-abdomen.html

Robotic Hysterectomy/BSO/Sentinel LND (Video)



Post-operative Care

Operating Room

Post-Anesthesia Care Unit (PACU)

- Observation for ~4 hours
- Regular diet, foley removal, IVF, O2 prn (to keep O2 sat >92%), IV pain meds/anti-emetics prn

Discharge

-Same day or next day (stay overnight x 1 night)
-Medications
  -analgesia (NSAIDs, Tylenol, opioids)
  -stool softener

Admission

-Peri-operative complications
  -i.e. urinary tract/bowel injury, bleeding, vaginal cuff dehiscence, conversion to laparotomy
-Comorbidities

Outpatient Post-op Appointment (~3-4 weeks)

UpToDate – Laparoscopic hysterectomy, 2022
Allscripts Gateway I Prodd 18.4 Applications I CIS – SDH_PACU_GYN_OP_PostOp, 2022
https://www.nfcr.org/cancer-types/uterine-cancer/

Low Grade Early Stage Endometrioid Endometrial Cancer

Prognosis

- Mainly based on disease stage, grade, and histology
  - Other: LUS/LVSI involvement, advanced age, Black race
- **5-year survival**
  - **Stage I ~80-90%**
  - **Stage II ~70-80%**

Low grade (grade 1 or 2)

+

Early stage

+

Endometrioid endometrial cancer

= Favorable prognosis

Uterine carcinoma: FIGO surgical stage and overall survival

FIGO stage	Five-year overall survival (%)
IA	90.3
IB	80.8
II	80.5
IIIA	68.5
IIIB	53.1
IIIC1	58.3
IIIC2	51.2
IVA	22.0
IVB	21.1

Data from: SEER database for patients treated in 1988 through 2006, staging in these patients includes lymphadenectomy, staged according to the 2010 FIGO staging system (from Obstet Gynecol 2010; 116:1141).

FIGO: International Federation of Gynecology and Obstetrics; SEER: Surveillance, Epidemiology, and End Results.

UpToDate®

UpToDate – Overview of endometrial carcinoma, 2022
UpToDate – Endometrial carcinoma: Clinical features, diagnosis, prognosis, and screening, 2022