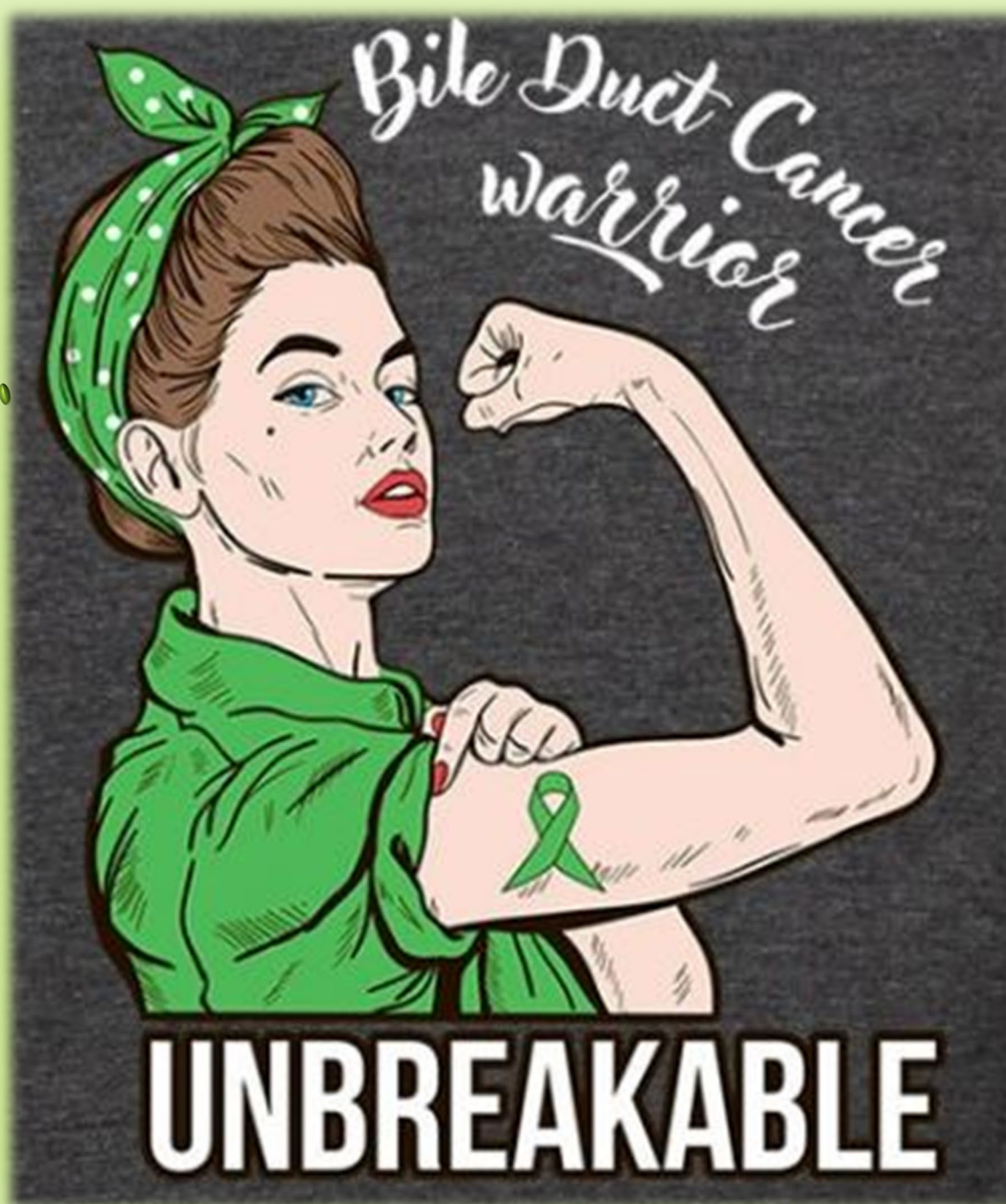
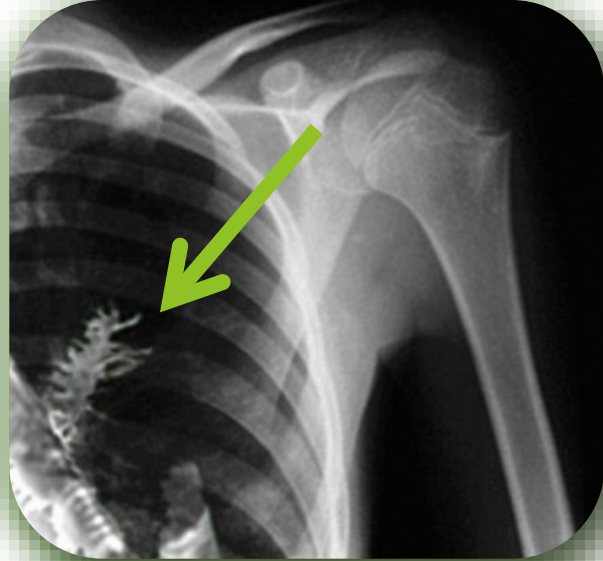

Carol's Journey...



Carol's Journey... Est. 2013-present

- ▶ Misdiagnosed a serious cough for 2yrs - Sinus drip and allergies
- ▶ I joked, there's a tree growing in my lungs!
 - ▶ *"A fir tree has been found growing inside a man's lung by Russian surgeons"*

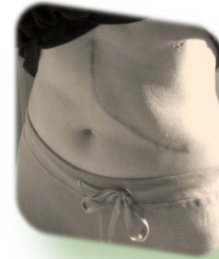

Carol's Journey... Est. 2013-present

- ▶ After severe pain in my side, which I thought was **gas**, I went into my local ER at the advice of a doctor friend....
- ▶ Diagnosis' found:
 - ▶ Pneumonia... *"ok, but what about the pain in my side?"*
 - ▶ Pleurisy/Collapsed lung... *"ok, but what about the pain in my side?"*
 - ▶ Gallstones... *"ok, but what about the pain in my side?"*
 - ▶ This went on all night until being admitted & ALL week long (NPO no less!)
- ▶ We can't find anything, time for discharge
 - ▶ Wait! let's run one more test...an MRI
- ▶ "The ambulance is waiting downstairs to transfer you to Robert Wood Johnson"
 - ▶ No Thank-you, I'm outta here!

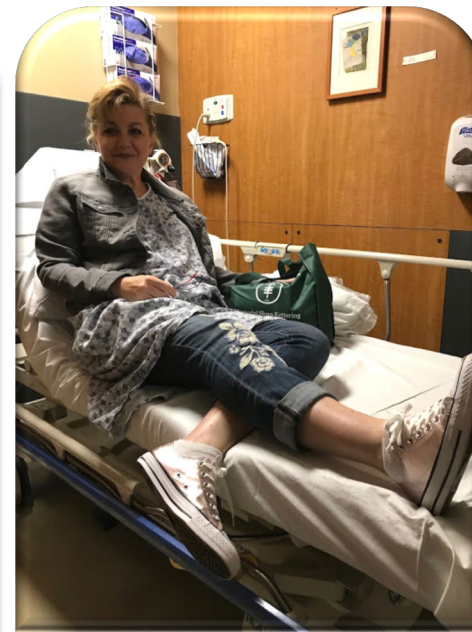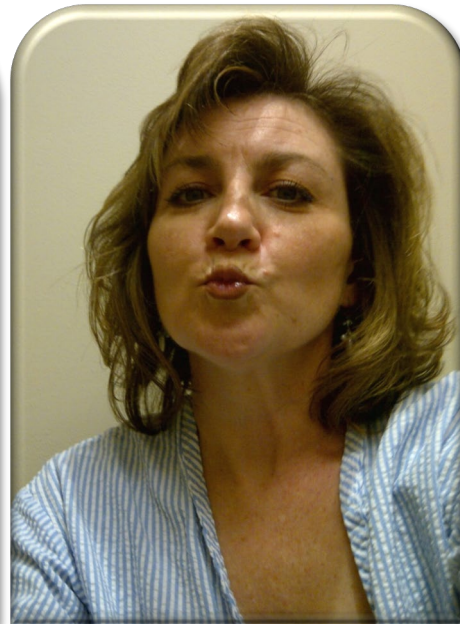Carol's Journey... Est. 2013-present

- ▶ Consulted with liver surgeon at Mt. Sinai Recanati/Miller Transplant Institute, for what was thought to be a large blood mass on the liver
- ▶ Surgical dissection August 2013
 - ▶ Liver mass 11cm extending through the diaphragm to the right lung
 - ▶ 2+ weeks waiting for results from pathology
- ▶ Initially referred to oncology at Mt. Sinai
 - ▶ Caris testing (molecular profile)
 - ▶ Various drug therapy choices presented
 - ▶ “I thought you wanted something sexy”
- ▶ Second opinion with MSKCC
 - ▶ Oncologists co-consulted initially
 - ▶ Transferred care/treatment to Memorial Sloan Kettering, Dr. Abou-Alfa



Carol's Journey... Est. 2013-present

- ▶ Various rounds of Chemotherapy, Radiation, Immunotherapy & trips to the UCC



Carol's Journey... Est. 2013-present

- ▶ Scores of hats and wigs over the years....

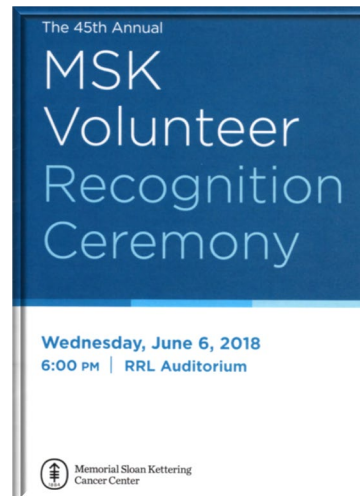


Carol's Journey... Est. 2013-present



Carol's Journey... Est. 2013-present

- ▶ Became an MSK PFACQ Volunteer in 2017 following MSK-Monmouth Grand Opening
- ▶ Graced cover of brochure for MSK-Bergen and included in the Annual Report in 2018



Carol's Journey... Est. 2013-present

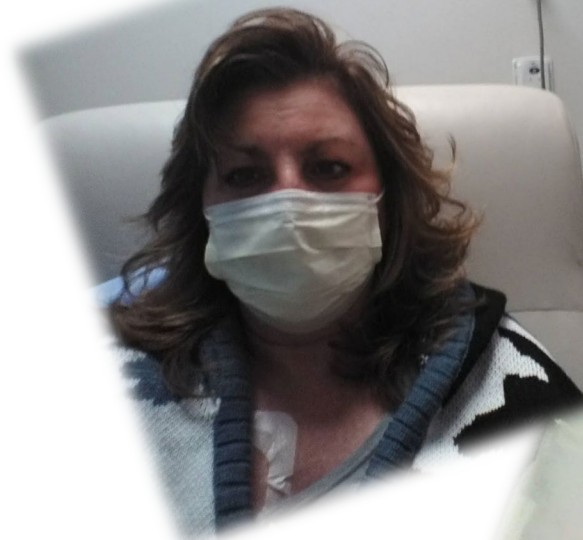► Treatment during Covid-19 pandemic



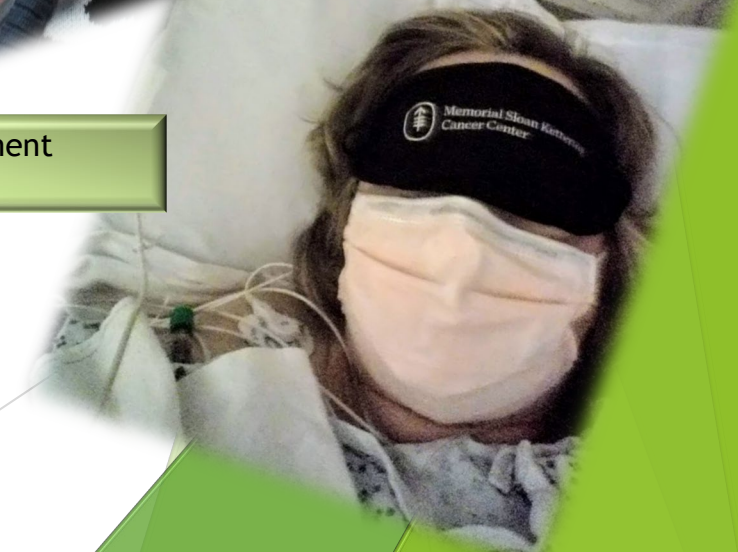Waiting in the outdoor garden



Home-made face shield!
duct tape, presentation velo-cover & foam



Receiving treatment
& Surgery - Solo!



Lessons Learned...

- ▶ Be your own advocate
 - ▶ Speak-up, ask questions, report symptoms no matter how small
- ▶ Educate yourself
 - ▶ About the disease, your treatment plan, etc.
 - ▶ Internal lingo and processes
 - ▶ The infamous “your drug is mixing”
- ▶ Keep records
 - ▶ Symptoms diary
 - ▶ Read your reports and track your results
- ▶ Appreciate the entire MSK team!
 - ▶ Little things mean a lot

Carol Cincotta
Historical Measurements from CT Scans

Date of CT Scan	Mammary Node	Lung: Left		Lung: Right		Right Liver Lesion
		Upper Lobe	Lower Lobe	Upper Lobe	Lower Lobe	
2013						
7/26/13 <small>(Monmouth Medical Ctr)</small>	1.6 x 1.6	3mm (?)	1.0 x .07	1.6 x 1.6 / (3mm ?)	No comments	No comments
10/3/13	1.8 x 1.6 (previously 1.7 x 1.2)	.8 x .8	1.0 x 0.8	No comment	1.7 x 1.2	Stable sub-centimeter too small to categorize low attenuation left hepatic lesions
12/18/13	Now Sub-centimeter	.5 x .4	.6 x .5	.04	1.7 x .06	Stable punctuate hypo densities in segment 3 & 5
2014						
1/13/14	Unchanged sub-centimeter	.5 x .4	.6 x .5	Stable bi-lateral pulmonary metastases	Stable bi-lateral pulmonary metastases 1.7 x .6	No comments
2/20/14	Stable .9 x .5	.3 x .3	.5 x .5	.4	1.4 x .06	Stable segment 8. Stable segments 3 & 5 too small to characterize
4/23/14	Stable 1 x .05	No comments	.5 x .4	.4	1.7 x .7	Stable segment 8. Stable segments 3&5 too small to characterize
7/16/14	Sub centimeter w/out significant change. Minimal thymic tissue anterior mediastinum again seen (?)	No comments	.5	.3	No comments	Stable, low-density (previous punctuate hypo density left lobe not conspicuous)

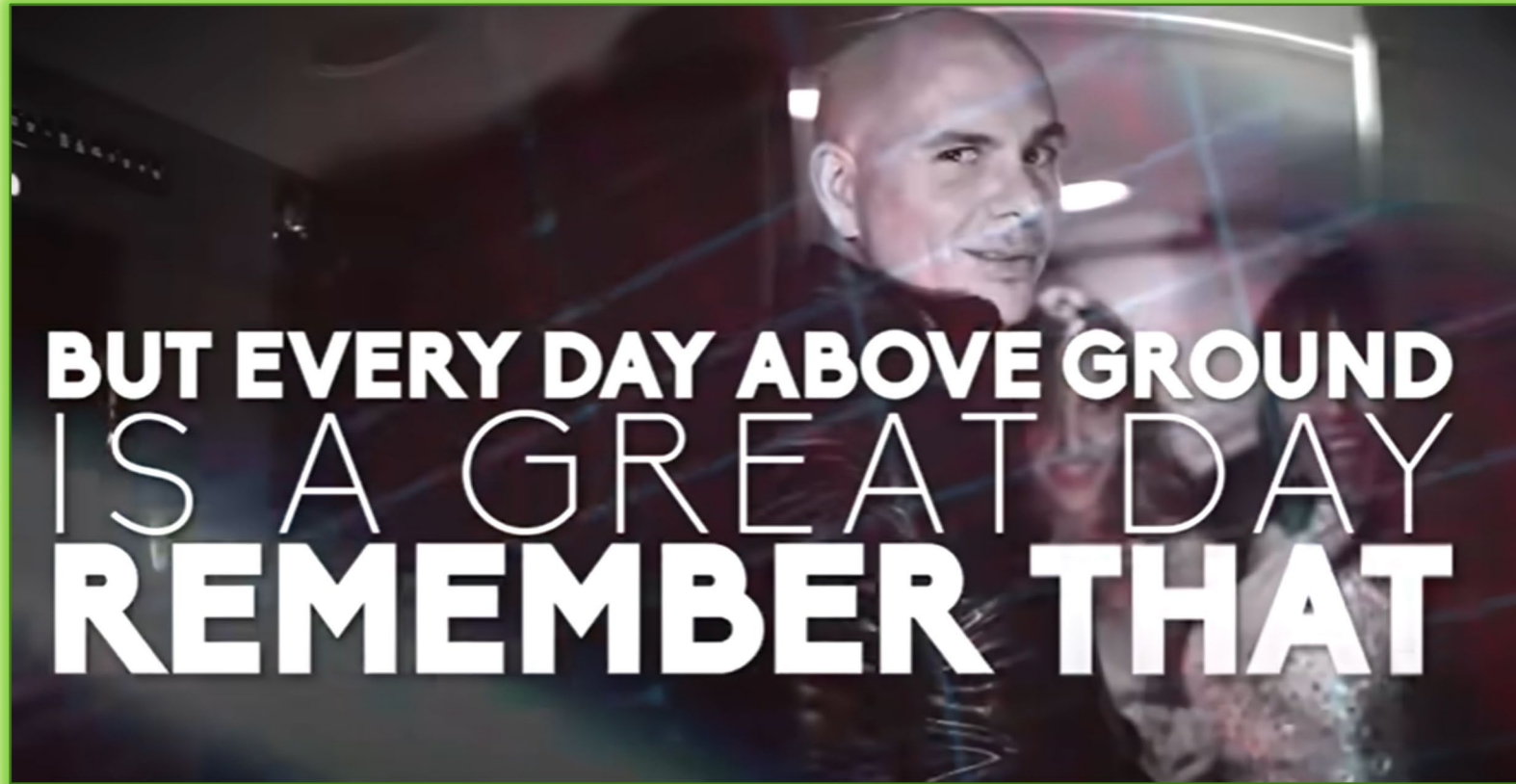Carol's Journey... Est. 2013-present

► Keep the Faith!



Joel Osteen;
pastor, televangelist, and author

For everybody going through tough times...



Pitbull, Ne-Yo - *Time of our Lives*

Join MSK's PFAC...

- ▶ Visit: ww.mskcc.org/about/patient-and-family-advisory-council-quality
- ▶ Call Elizabeth Dunlop at [646-888-5803](tel:646-888-5803) (or) email: pfacq@mskcc.org

Start your own PFAC...

- ▶ **Institutional Readiness** – find a key partner or champion that will help develop trust between PFACQ and hospital leadership.
- ▶ **Governance and Recruitment** – develop structure including membership, term limits, and elections. Create mission and vision statements.
- ▶ **Presence and Awareness** – speak to various departments and groups to spread awareness of PFACQ's value and work. Find partners that understand the value of PFACQ.
- ▶ **Set Priorities** – determine which projects can benefit from PFACQ participation and are meaningful collaborations and involve members from early development.
- ▶ **More Resources can be found** – **Institute of Patient and Family Centered Care Website**

www.ipfcc.org/bestpractices/patient-and-family-advisory-programs/pfa-resources-and-tools.html



peace ♡ love ♡ cure

BILE DUCT CANCER/CHOLANGIOCARCINOMA AWARENESS